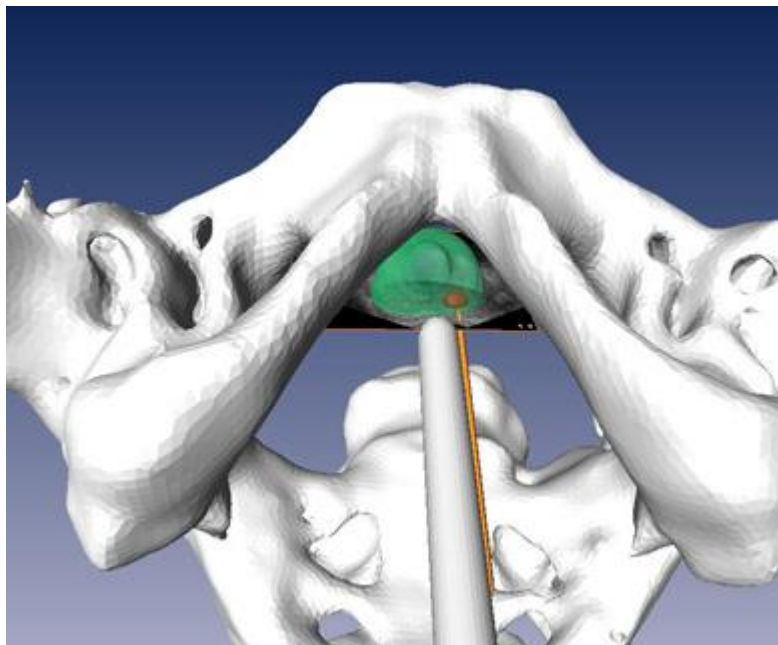

PRECISION IMAGING: QUANTITATIVE, MOLECULAR AND IMAGE- GUIDED TECHNOLOGIES



Module 2: Fluciclovine PET-CT Directed 3D Ultrasound Guided Biopsy

Funmilayo Tade MD, Oladunni Akin-Akintayo MD, Akinyemi Akintayo MD, Olayinka Abiodun-Ojo, David Schuster MD, Baowei Fei, PhD.

INTRODUCTION

Fluciclovine is an amino acid based radiotracer approved by the FDA for PET-CT imaging of recurrent prostate cancer.

In recurrent prostate cancer patients, transrectal ultrasound (TRUS) guided biopsy is the clinically preferred method. However, the low ability of ultrasound techniques to differentiate malignant from benign or post-therapy changes makes ultrasound-guided prostate biopsy suboptimal.

TRUS biopsy technique has been shown to have sampling error with a cancer detection rate of about 7% per core. Patients missed are probably those in early stage recurrent prostate cancer evidenced by rising PSA post-definitive therapy.

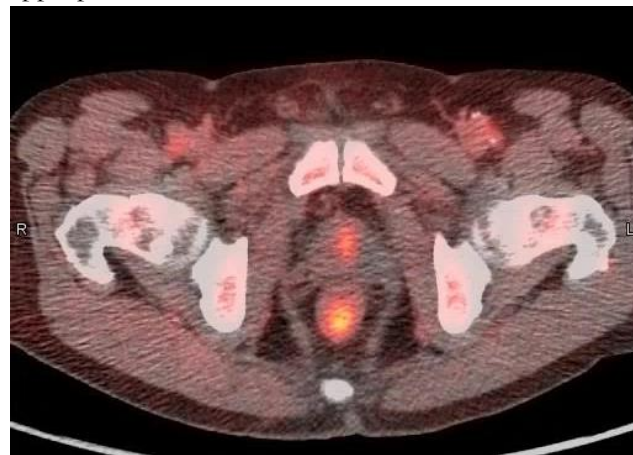The fluciclovine PET-CT guided 3D ultrasound-guided prostate biopsy study was initiated to determine the utility of this novel technique to improve prostate biopsy detection rates in recurrent prostate cancer patients. Preliminary results have been encouraging with a cancer detection rate of 47.6% per patient vs 28.6% detection rate on standard template biopsy.

GOAL

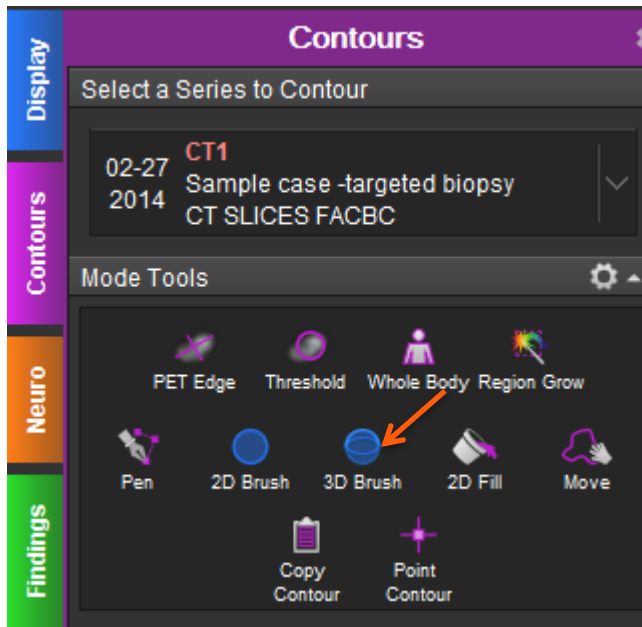
At the end of this training, you should be able to outline the prostate and draw region of interests (ROI) on locations in the prostate that are suspicious for prostate cancer

PROCESS

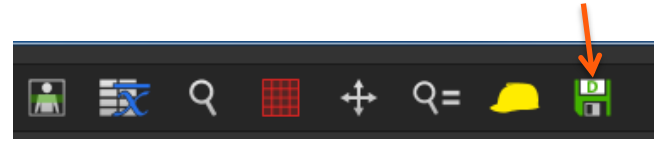
- 1) Select the PET and CT images and open with the appropriate workflow on MimVisata workstation



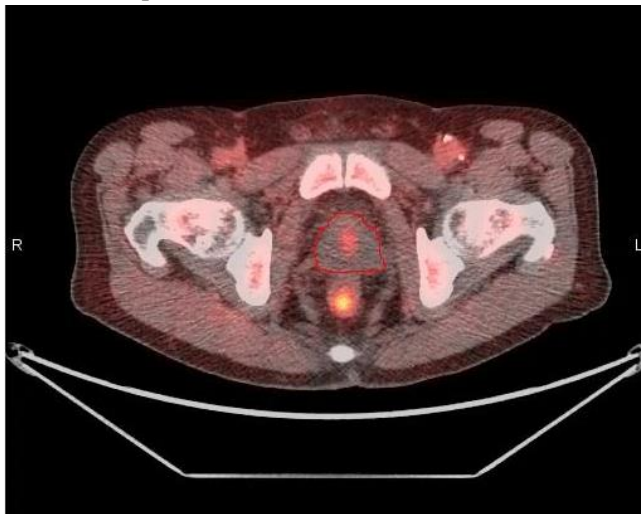
- 2) select the 3D brush from the contour mode tools



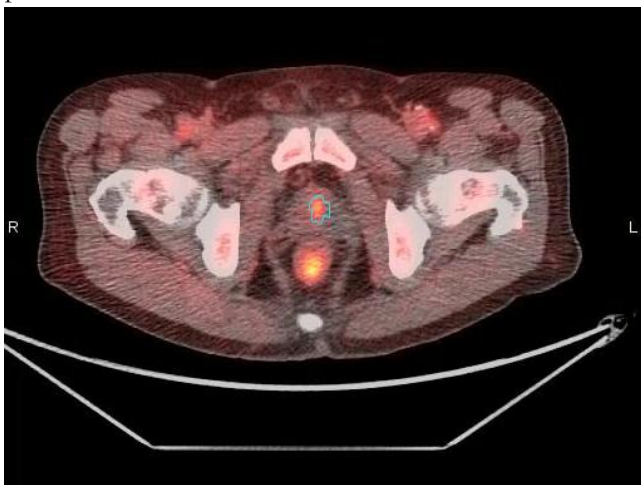
- 5) Save your session by selecting the save button on the tool bar, choose "save session" and enter your initials as the operator



- 3) Outline the prostate



- 4) Then draw ROI on individual lesion(s) in the prostate



SAMPLE CASES

- I. Open the precision imaging folder on MimVista workstation and select the “sample case”
- II. By following the process earlier shown, outline the prostate and draw ROIs in the locations suspicious for prostate cancer
- III. Ensure to save your session
- IV. Open the saved session under the “sample case”
- V. Compare your outline and ROIs to that of the saved session of an expert

TEST CASES

- I. Repeat same process as above
- II. Open the saved session under “test case”
- III. Compare your outline and ROIs to the saved session of an expert

Indicate in the Fluciclovine column if you found disease or not in the prostate.

| | Template Biopsy | Fluciclovine PET | Pathology | TRUTH (TP/ FP) |
|---------------|-----------------|------------------|-----------|----------------|
| Sample case 1 | Negative | | | |
| Sample case 2 | Negative | | | |
| Sample case 3 | Positive | | | |

DETECTION RATE: $TP/TP+FP$

CASE SUMMARIES

(Note: Each case has only one lesion)

SAMPLE CASE 1

67yr old with biochemical failure post-brachytherapy for prostate cancer, PSA 3.55ng/ml

SAMPLE CASE 2

55yr old with biochemical failure post-brachytherapy for prostate cancer, PSA 4.0ng/ml

SAMPLE CASE 3

73yr old with biochemical failure external beam radiation for prostate cancer, PSA 3.4ng/ml

TRUTH

Use this information to determine the detection rate of recurrent prostate cancer on:

- I. Template biopsy
- II. Fluciclovine-3D targeted fusion biopsy

CASE 1

Prostate biopsy negative on standard template biopsy, but positive on Fluciclovine-3D targeted fusion biopsy, Gleason score 4+3=7.

CASE 2

Prostate biopsy negative on both standard template biopsy and Fluciclovine-3D targeted fusion biopsy.

CASE 3

Prostate biopsy positive on both standard template biopsy and Fluciclovine-3D targeted fusion biopsy. Gleason score 3+4=7.